

Moderate–severe traumatic brain injury causes delayed loss of white matter integrity: Evidence of fornix deterioration in the chronic stage of injury

Areeba Adnan, Adrian Crawley, David Mikulis, Morris Moscovitch, Brenda Colella & Robin Green

To cite this article: Areeba Adnan, Adrian Crawley, David Mikulis, Morris Moscovitch, Brenda Colella & Robin Green (2013) Moderate–severe traumatic brain injury causes delayed loss of white matter integrity: Evidence of fornix deterioration in the chronic stage of injury, *Brain Injury*, 27:12, 1415-1422, DOI: [10.3109/02699052.2013.823659](https://doi.org/10.3109/02699052.2013.823659)

To link to this article: <https://doi.org/10.3109/02699052.2013.823659>



Published online: 08 Oct 2013.



Submit your article to this journal [↗](#)



Article views: 412



View related articles [↗](#)



Citing articles: 27 View citing articles [↗](#)

ORIGINAL ARTICLE

Moderate–severe traumatic brain injury causes delayed loss of white matter integrity: Evidence of fornix deterioration in the chronic stage of injury

Areeba Adnan¹, Adrian Crawley², David Mikulis², Morris Moscovitch^{3,4}, Brenda Colella⁵, & Robin Green⁵

¹Toronto Rehabilitation Institute, Toronto, ON, Canada, ²Department of Medical Imaging, Division of Neuroradiology, University Health Network, University of Toronto, Toronto, ON, Canada, ³Department of Psychology, University of Toronto, Toronto, ON, Canada, ⁴Rotman Research Institute, Baycrest Centre for Geriatric Health, Toronto, ON, Canada, and ⁵Toronto Rehabilitation Institute, University Health Network, Toronto, ON, Canada

Abstract

Objectives: To examine structural integrity loss in the fornix from 5–30 months after moderate and severe traumatic brain injury (TBI) using diffusion tensor imaging.

Methods: MRIs were prospectively undertaken in 29 adults with moderate and severe TBI at two time points. Fractional anisotropy (FA) was calculated for the fornix (column/body, right crux and left crux) at 5 and 30 months post-injury.

Results: Paired *t*-tests revealed significant FA reductions with large effect sizes across time in the column/body, $p < 0.001$, right crux, $p < 0.001$ and left crux, $p < 0.001$.

Conclusions: These data contribute to the growing body of evidence that loss of white matter continues in moderate and severe TBI even after the acute neurological effects of TBI have resolved. As the fornix plays a critical role in memory, this may be a contributing factor to the poor clinical outcomes observed in these patients.

Keywords

Chronic brain injury, diffusion tensor imaging, fornix, fractional anisotropy, neurodegeneration, traumatic brain injury

History

Received 20 November 2012

Revised 26 May 2013

Accepted 10 June 2013

Published online 3 October 2013

Abbreviations: DAI, Diffuse axonal injury; DTI, Diffusion Tensor Imaging; FA, Fractional Anisotropy; FSL, Functional Magnetic Resonance Imaging of the Brain Software Library; FMRIB, Functional Magnetic Resonance Imaging of the Brain; FNIRT, FMRIB's non-linear image registration tool; FDT, FMRIB's Diffusion Toolbox; BET, Brain Extraction Tool; ROI, Region of Interest; MRI, Magnetic resonance imaging; SPGR, Spoiled-gradient recalled-echo; TBI, Traumatic Brain Injury; TAI, Traumatic Axonal Injury; TBSS, Tract-Based Spatial Statistics

Introduction

Moderate-to-severe traumatic brain injury (TBI) is associated with enduring and debilitating behavioural impairments, particularly in the areas of memory, attention, executive functioning and regulation of emotional functioning [1, 2]. The cause of these behavioural impairments is typically associated with the acute effects of injury, in which impact and acceleration, deceleration and rotational forces result in a host of deleterious events. Acute effects can include shearing and transection of axons and blood vessels along with contusions and lacerations; these may be followed minutes to days later by metabolic, excitotoxic and hypoxic damage, inflammation, oedema, reductions to cerebral blood flow and haemorrhages causing mass effects [2–5].

While acute events can represent massive damage to the brain, there is growing evidence that there is further damage that occurs at some point after these acute events have

resolved. Several studies have now revealed losses to grey and white matter tissue in human adults in the sub-acute and chronic stages of injury [6–10]. This group has demonstrated significant reductions in volume of the whole brain and hippocampus, as well as lesion expansion and loss of white matter integrity in deep frontal and temporal regions in 14 patients with moderate-severe TBI from 5 to 30 months post-injury [8, 9]. These findings represent a deviation from the prevailing view of brain lesions as static, following resolution of acute neurological events and encephalomalacia. Understanding the presence and nature of these putative sub-acute and chronic changes would open up the door to new areas of treatment research.

The loss of integrity of white matter is of particular clinical importance, as compromise to white matter underlies the majority of clinical impairments in TBI [11]. Moreover, it is in the new growth of axon collaterals, as well as dendritic spine modifications, where the synaptic modification and synaptogenesis underlying beneficial neuroplastic change is most promising [12]. *In vivo* studies of white matter integrity in human TBI have typically employed diffusion tensor imaging (DTI) [6, 8, 13], which has greater

Correspondence: Robin Green, PhD, Toronto Rehabilitation Institute, University Health Network, 550 University Ave, Toronto, ON M5G 2A2, Canada. Tel: 416-416-597-3422 ext 7871. Fax: 416-597-7101. Email: robin.green@uhn.ca

demonstrated sensitivity to white matter abnormalities than conventional MRI [8, 14, 15]. Fractional Anisotropy (FA) is the most common metric used in DTI and is used to describe the degree of elongation or diffusion directionality. A high FA within a single voxel indicates that diffusion occurs predominantly along a single axis [16]. A large number of DTI studies have characterized the acute effects of white matter injury in TBI [14, 15, 17–22]. However, the number of longitudinal studies characterizing the progression of white matter damage into the later stages of injury, commencing after the acute neurological effects of injury have resolved, is much smaller.

Of those studies examining the sub-acute and chronic effects of white matter injury, even fewer have focused on the fornix. The fornix is of particular interest because it connects the hippocampus to the mammillary bodies and plays a key role in memory [23, 24] and the authors and others have observed atrophy of the hippocampi in the later stages of TBI [9, 23]. However, the fornix's long, thin and curved morphology makes its integrity difficult to assess. Indeed, of all the studies examining white matter in the traumatically injured human brain *in vivo* at all stages of injury, only eight were found examining the fornix [19, 25–30]. Amongst these, only three were longitudinal and prospective, examining changes over time [26, 30]. The first, conducted by Hong and Jang [26], was a case study, which showed significant loss of FA from 3 to 19 months post-injury. The second, by Zhan et al. [30], assessed *mildly* brain injured patients at 6 weeks and again at 6 months post-injury and found significantly reduced FA values across assessments. The third [31] examined the fornix, amongst other regions, in a sample of 12 patients at three time points, who were assessed at 2 months post-injury, ~1 year later and then ~3 years after the second visit. This study found no evidence of progression over time in the fornix. Therefore, further research into the change in the fornix over time is warranted, given the importance of the white matter changes in the clinical presentation of TBI, the role of the fornix in memory, the somewhat inconsistent findings in the literature and, finally, the broader importance of the question of whether brain damage progresses with time.

The current study prospectively examined FA changes from 5 to 30 months post-injury in 29 patients recruited from an in-patient neurorehabilitation programme with a mean Glasgow Coma Scale score in the severely injured range. The initial time of assessment was later than in previous studies, in a conservative effort to ensure that the acute effects of injury, including oedema, had had sufficient time to resolve and that encephalomalacia was stable. Based on previous findings in the fornix [26, 30] as well as previous longitudinal research [8], it was hypothesized that a significant decline in fornix integrity would be observed across time.

Materials and methods

Participants

This study was approved by the research ethics board of the institution where the research was undertaken. All participants provided their informed consent.

The participants were part of an ongoing prospective study of cognitive and motor recovery from TBI involving repeated MRI assessment. Table I shows all available demographic and

Table I. Demographic and clinical characteristics of patients included in the study.

Age, mean (SD)	40.57 (15.29)
Distribution of patients by decade of age, <i>n</i> *	
<20 years: <i>n</i> = 3	
20–30 years: <i>n</i> = 8	
31–40 years: <i>n</i> = 2	
41–50 years: <i>n</i> = 7	
51–60 years: <i>n</i> = 8	
61–70 years: <i>n</i> = 1	
Years of education, mean (SD), <i>n</i> = 29	13.89 (3.47)
Acute care length of stay, mean (range), <i>n</i> = 28	37.63 (11–87)
Lowest Glasgow Coma Scale score, mean (range), <i>n</i> = 27	6.94 (3–13)
Length of post-traumatic amnesia, mean (range), <i>n</i> = 28	5 (4–6)
Classification Scale for LPTA [58]	
1. <5 minutes very mild	
2. 5–60 minutes mild	
3. 1–24 hours moderate	
4. 1–7 days severe	
5. 1–4 weeks very severe	
6. more than 4 weeks extremely severe	
Injury type	
Motor vehicle Accident, <i>n</i> (%)	12 (41.38)
Motor vehicle Accident–pedestrian, <i>n</i> (%)	3 (10.34)
Fall, <i>n</i> (%)	13 (44.83)
Hit, <i>n</i> (%)	1 (3.45)

*Number of subjects with data for each demographic/injury classification.

clinical characteristics of participants. Note that, where two valid GCS scores are available, the lowest is used to best capture injury severity. (GCS may decline with time due to evolving oedema and/or haemorrhage.)

Key inclusion criteria for the larger study were a clinically diagnosed brain injury of sufficient severity to warrant inpatient neurorehabilitation; age 18–80; functional use of at least one upper extremity; and out of post-traumatic amnesia as of 2 months post-injury. Subjects were excluded from the larger study if they had a diagnosis of a disease affecting the central nervous system (e.g., Alzheimer's disease, multiple sclerosis); a history of psychotic disorder; or a TBI acquired secondary to another brain injury (e.g., stroke). Patients were eligible for the current study if they had completed their 5-month and 30-month post-injury MRI assessments. They were ineligible if they sustained a new neurological event (e.g., stroke, TBI) between the two assessments of the study. There were 33 eligible patients at the time of the study four were lost to follow-up, leaving 29 patients. Thus, the retention rate was 88%, which is high compared with other longitudinal studies of TBI.

Acquisition

All MRI scans were acquired on a GE Signa-Echospeed 1.5 Tesla scanner using a standard quadrature head coil. The high-resolution 1 mm isotropic T1 weighted, three dimensional radio-frequency spoiled-gradient recalled-echo (SPGR) images were acquired in the axial plane (TR = 11.74 ms, TE = 5.14 ms and flip angle = 20°, 160 slices). DTI data for each subject was acquired using a diffusion-weighted spin echo single-shot echo-planar imaging sequence with diffusion encoding in 26 non-collinear directions. The sequence parameters were as follows: repetition time = 8300 ms;

matrix, 128×128 ; field of view, 30×30 cm; 5-mm thickness; 0-mm gap; b factor, 1000 s mm^{-1} .

DTI data processing and region of interest (ROI) analysis for the fornix

First, the Digital Imaging and Communications in Medicine files of each DTI acquisition were converted to a single multivolume 4D format in the MRICron software [32] to be analysed in the Functional Magnetic Resonance Imaging in the Brain (FMRIB) Software Library (FSL) [33, 34]. Next, they were corrected for effect of head movement and eddy current distortion using the eddy correct tool in FMRIB's Diffusion Toolbox (FDT), a part of FSL. This tool conducts an affine registration of each individual volume to a specified b0 volume.

Brain tissue was segmented using the Brain Extraction Tool (BET) [35], a part of FSL [33, 34] and a brain mask was created at a specified threshold. The FDT tool was then used in FSL to fit a diffusion tensor model at each voxel in the brain-extracted images created from the BET tool and created FA images for each scan. Voxelwise statistical analysis of the FA data was carried out using Tract-Based Spatial Statistics (TBSS) [36], part of FSL [33]. All subjects' FA data were then aligned into a common space using the non-linear

registration tool FNIRT [37, 38], which uses a b-spline representation of the registration warp field [39]. The common space of choice was the ICBM-DTI-81 atlas. The atlas contains 50 white matter tract labels created from a standard-space averaging of DTI maps from 81 subjects. FA values for the (1) right crux, (2) left crux and (3) column/body of the fornix were obtained using ROI analyses in FSL based on the ICBM-DTI-81 1 mm atlas for the initial and follow-up scan. Figure 1 shows the ROI from the atlas placed onto a patient brain used in the study.

Design and procedures

The study employed a prospective, repeated-measures design. All patients underwent two MRIs. The first was carried out at a mean of 5.08 (SD = 1.09) months post-injury. The second was undertaken at a mean of 30.55 (SD = 7.18) months post-injury.

Statistical analysis

Differences across time were tested by conducting one-tailed, paired *t*-tests on the FA values for each subsection of the fornix in the 5-month vs. 30 months post-injury groups; effect size was measured with Cohen's *d*.

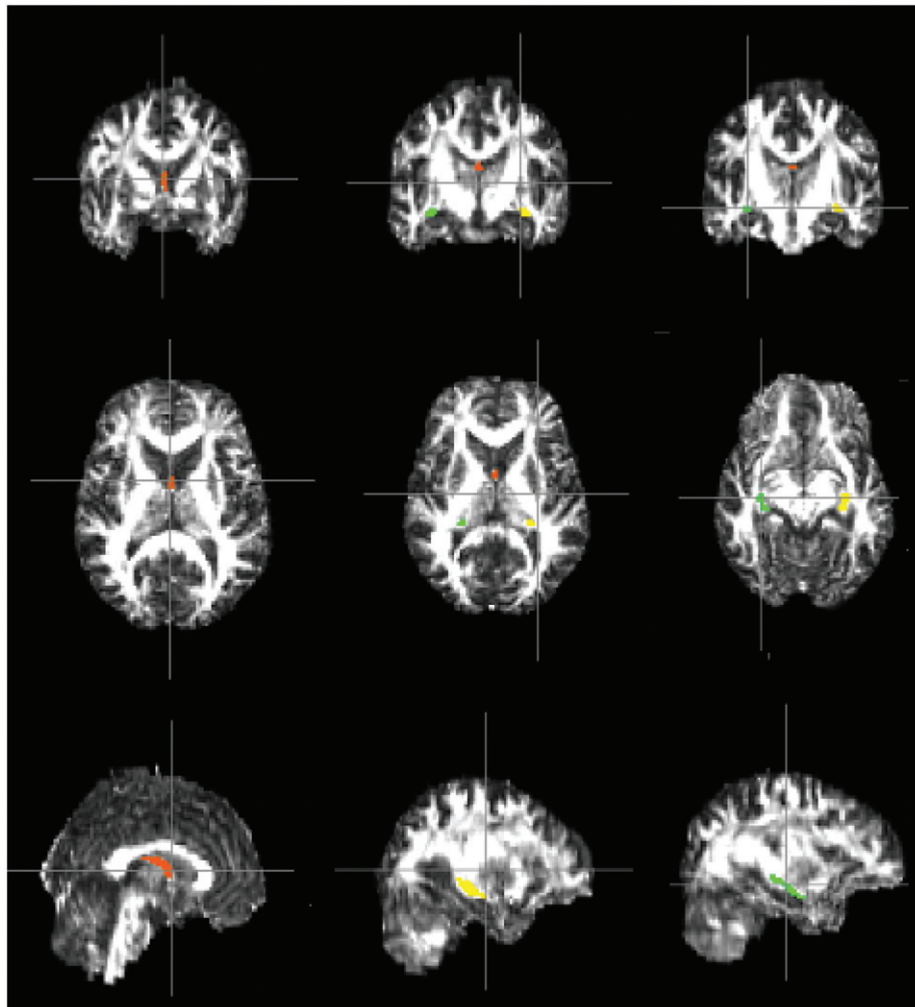


Figure 1. Coronal (top row), axial (middle row) and sagittal (bottom row) view of FA maps for a TBI patient with the JHU-ICBM-DTI-81 atlas fornix labels; orange: column/body of fornix, green: right crux of fornix, yellow: left crux of fornix.

In order to examine the possible contribution of ageing-related effects (during the 5–30 month post-injury period) as an explanation for any FA reductions observed, a secondary analysis of published data was conducted [40]. The purpose was to descriptively compare FA changes over time to those in a normative sample, following the precedent of Ng et al. [9]. The normative data was used of Jang et al. [40], who carried out a cross-sectional analysis of the column, body and crux of the fornix in healthy adults that included young adults (20–39 years, mean age = 28.9 years) and middle-aged adults (40–59 years, mean age = 48.9 years). To compare change over time in the data to change over time in the normative sample, annual percentage change was calculated using the following formula to produce a common time scale for both groups:

$$\left(\frac{[FA_{t1} - FA_{t2}]/(\text{average } FA_{t1} \text{ and } t2)}{(\text{time between scan 1 and scan 2})} \right) \times 100$$

The Jang et al. [40] study utilized similar pre-processing steps to these methods, but different post-processing and ROI analysis. (See Jang et al. [40] for a detailed description of processing methods.) More specifically, this study employed automated and pre-established masks publically made available by Mori et al. [41] from the ICBM-DTI-81 atlas; the Jang et al. [40] study used individual-specific ROI's. They subdivided the fornix into the column of fornix, the body of fornix and the crux (right and left) while the ICBM-DTI-81 atlas used in this study combines the column and body of fornix and separates the right and left crux. Thus, for comparison purposes, the mean of the column of the fornix and body of fornix were taken from their study in calculating percentage change and the mean of the right and left crux was taken from this data in order to calculate percentage change.

Finally, the possible moderating role of age in FA change over time was examined by correlating FA change with patient age (at time of the first assessment) for each component of the fornix using Pearson Product Moment correlations.

Results

Figure 2 shows the respective FA of each participant for the column/body, right crux and left crux of the fornix at 5 and 30 months post-injury. As can be seen, 21 patients showed absolute change in a negative direction in all sub-structures and 27 showed absolute declines in at least one sub-structure. Two participants showed absolute increases in FA values in all three sub-structures. A further three showed increases in two of three and, finally, three participants showed FA increases in one of the three sub-structures.

Figure 3 presents the findings for the column/body, right crux and left crux of the fornix. The omnibus one-tailed paired *t*-test revealed significant differences in FA values from 5 to 30 months for the column/body of fornix ($M = 0.28$, $SD = 0.05$ and $M = 0.25$, $SD = 0.047$, first and second assessments, respectively), $t(28) = 4.19$, $p > 0.001$, $d = 0.50$, the right crux ($M = 0.35$, $SD = 0.05$ and $M = 0.33$, $SD = 0.04$, first and second assessments, respectively), $t(28) = 4.05$, $p > 0.001$, $d = 0.53$, and the left crux ($M = 0.37$, $SD = 0.05$

and $M = 0.35$, $SD = 0.04$, first and second assessments, respectively), $t(28) = 4.12$, $p > 0.001$, $d = 0.54$.

In examining the role of ageing on FA losses over time, correlational analyses revealed no statistically significant relationship between age and degree of FA change for the column/body, $r(28) = -0.28$, $p = 0.15$; right crux, $r(28) = 0.029$, $p = 0.89$ or left crux of the fornix, $r(28) = 0.097$, $p = 0.62$.

Finally, in descriptively comparing FA changes in this sample to secondarily analysed published normative data, the mean annual percentage change in the left and right crux combined was -0.71% in the normative data. The mean annual percentage decline in this sample in the left and right crux combined was -3.37% , representing nearly a 5-fold difference in FA change. The mean annual percentage change in the normative data for the column and body combined was -0.73% . The mean annual percentage change in this sample for the column-body was -5.31% , which was more than 7-times the normative FA change.

Discussion

Commencing many months after acute injury, this study observed highly significant FA declines over time in the right crux, left crux and column/body of fornix. Ageing did not appear to account for substantive outcome variance. When the correlation was examined between age and degree of white matter change, the relationship was non-significant, with very small effect sizes. In order to further investigate the role of age on FA values, annual percentage decline was computed in a secondary analysis of published normative data. It was found that FA decline in this sample was 5–7-times that of the normative sample.

The current findings converge with two previous longitudinal studies of the fornix: the case study of Hong and Jang [26] and the study of mild TBI undertaken by Zhan et al. [30]. The findings are also consistent with a prior study examining loss of white matter integrity in deep temporal and frontal lobe regions at the same time points in a sub-set of these patients [8]. Farbota et al. [31] did not find ongoing changes in the fornix in their smaller sample of 12 patients that examined a range of ROIs, although the analyses that combined ROIs may have had insufficient power to detect changes.

A number of physiological mechanisms have been proposed for ongoing loss of white matter integrity, including persisting inflammation [42–45] and delayed apoptosis [46–50], gradual deafferentation [46, 48], protein deposition, with studies showing beta-amyloid precursor protein in compromised axons [48, 51, 52] and evidence of tau deposition years after a single moderate–severe TBI [53, 54] (see also Ng et al. [9] for discussion).

While the growing evidence of continued damage of the brain following acute brain injury recovery is discouraging, some findings from an animal model of mild-to-moderate TBI offer evidence that, at least in milder injuries, positive neuroplastic changes do occur subsequent to losses. Greer et al. [55] found that diffuse injury to white matter of a mild-to-moderate degree of severity, even in close proximity to the cell body, resulted in atrophy of the soma, but not cell death,

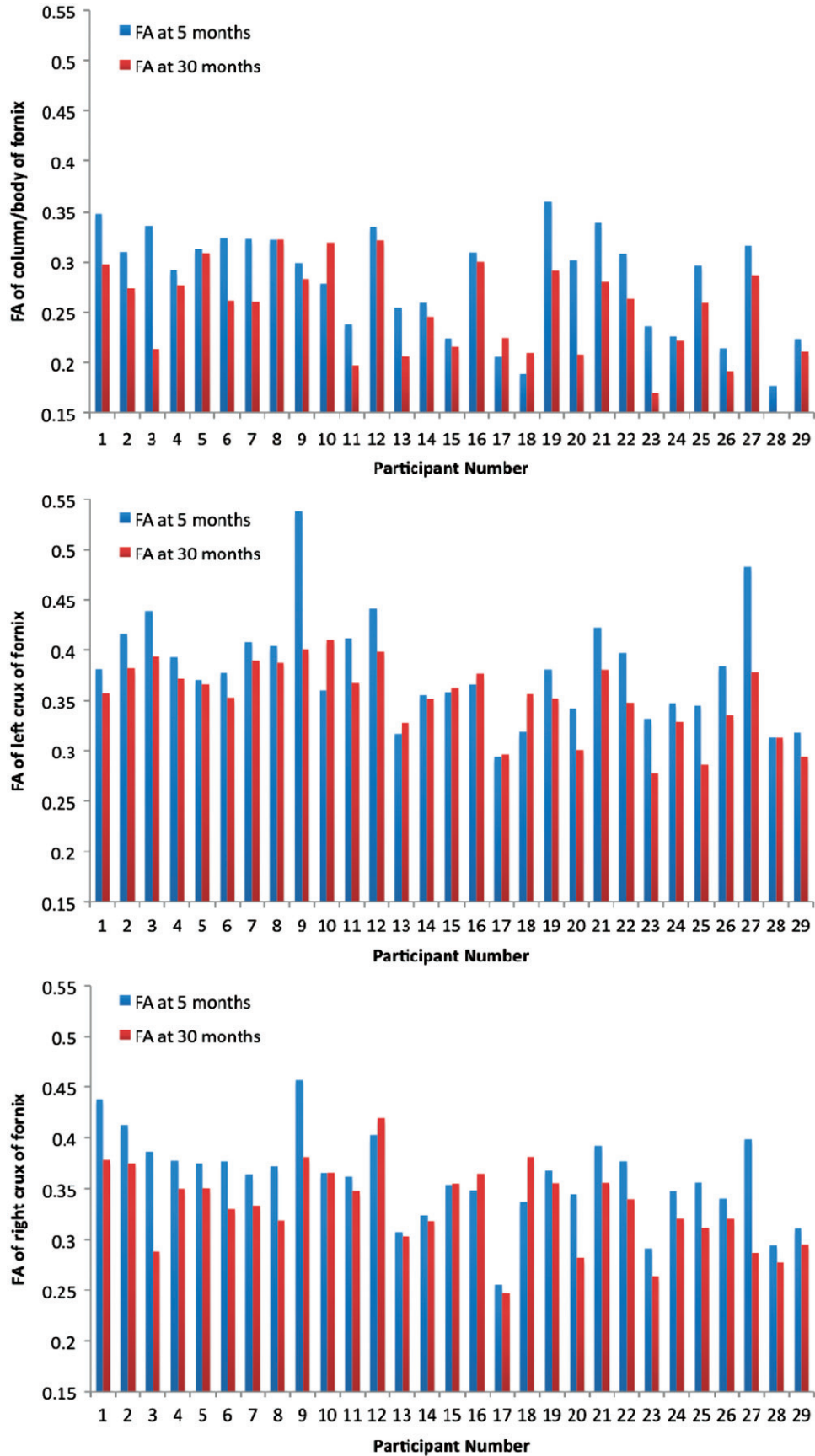
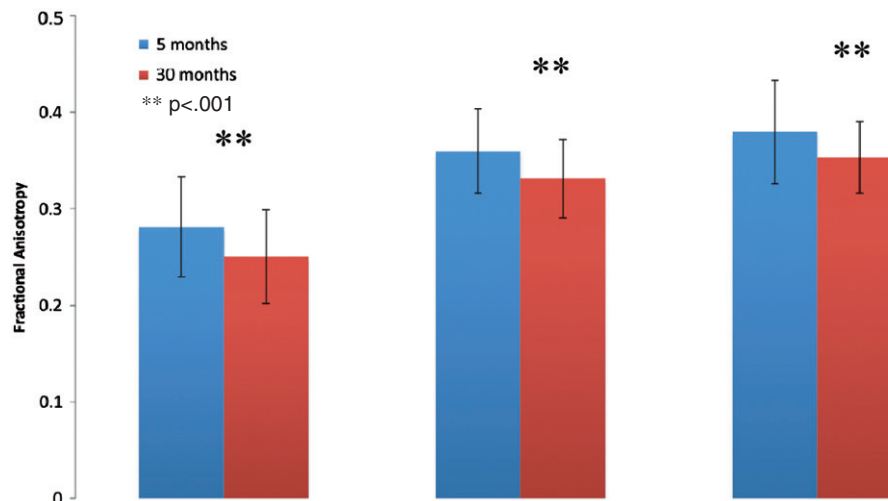


Figure 2. FA for column/body of fornix, right crux of fornix, left crux of fornix at each assessment for each participant included in the study.

Figure 3. Mean Fractional Anisotropy of the column/body (left), right crux (middle) and left crux (right) of the fornix at five and 30 months post injury.



and found evidence of regeneration within the damaged sub-cortical white matter, with elongation of the severed, truncated axons proximal to the cell body well into grey matter and terminating underlying layer V of the cortex.

Taken together, the current and previous white matter findings from this laboratory [8] and from other laboratories around the world [6, 43] raise the clinically and scientifically important question of whether brain injury is a progressive entity [45, 56, 57]. This postulation deviates from the prevailing view that, following the recovery of acute neurological events, the TBI brain is relatively stable. Indeed, the findings suggest that, in the sub-acute and chronic stages of injury, change is likely caused by multiple competing mechanisms, both beneficial (e.g., unmasking, functional reorganization and regeneration) and deleterious [59].

Limitations

This study lacked a control sample within the same experiment to control for the effects of ageing-related loss of white matter integrity. The recent study by Jang et al. [40] allows one to coarsely examine this potential confound. The Jang et al. normative data were cross-sectional and the comparison between this study and these data assumes linear change over time. However, the findings help to partially rule out ageing-related decline as an explanation for the significant drop in FA across time. In addition, this study did not find effects of ageing, *per se*, on FA loss.

Second, the current data do not allow one to ascertain at what point during the 5 and 30 months-post injury gap the FA losses occurred, nor whether the losses were discrete or gradual. This raises the interesting empirical question of whether, if these changes occur over time, they follow a linear course, a downward acceleration or slowing and self-limiting path.

Conclusions

TBI is associated with FA reductions in the fornix well after resolution of acute neurological events has taken place. These results contribute to a growing body of literature revealing that TBI is not a static disorder in the later stages of the disorder. The findings support the need to consider a

reconceptualization of TBI as a chronic and possibly progressive disorder. Further research with more refined timelines is needed to better understand the trajectory of these changes, their underlying mechanisms, their ubiquity and the underlying causes. Such research would permit better care-path planning as well as new avenues for treatment research into offsetting these deleterious changes.

Acknowledgements

We thank Yuko Koshimori, MSc and Zeyu Li for their help with DTI analyses.

Declaration of interest

The authors acknowledge the support of Toronto Rehabilitation Institute, Canadian Institute of Health Research, Physicians Services Incorporated Foundation, the Ontario Neurotrauma Foundation, and the Canada Research Chairs Program. The authors report no conflicts of interest.

References

1. Lipton ML, Gulko E, Zimmerman ME, Friedman BW, Kim M, Gellella E, Gold T, Shifteh K, Ardekani BA, Branch CA. Diffusion-tensor imaging implicates prefrontal axonal injury in executive function impairment following very mild traumatic brain injury. *Radiology* 2009;252:816–824.
2. Povlishock JT, Katz DI. Update of neuropathology and neurological recovery after traumatic brain injury. *Journal of Head Trauma Rehabilitation* 2005;20:76–94.
3. Buki A, Povlishock JT. All roads lead to disconnection? - Traumatic axonal injury revisited. *Acta Neurochirurgica (Wien)* 2006;148:181–194.
4. Adams JH, Graham DI, Murray LS, Scott G. Diffuse axonal injury due to nonmissile head injury in humans: An analysis of 45 cases. *Annals of Neurology* 1982;12:557–563.
5. Gennarelli TA, Thibault LE, Adams HJ, Graham DI, Thompson CJ, Marcincin RP. Diffuse axonal injury and traumatic coma in the primate. *Annals of Neurology* 1982;12:564–574.
6. Bendlin BB, Ries ML, Lazar M, Alexander AL, Dempsey RJ, Rowley HA, Sherman JE, Johnson SC. Longitudinal changes in patients with traumatic brain injury assessed with diffusion-tensor and volumetric imaging. *Neuroimage* 2008;42:503–514.
7. Bigler ED, Kurth SM, Blatter D, Abildskov TJ. Degenerative changes in traumatic brain injury: Post-injury magnetic resonance identified ventricular expansion compared to pre-injury levels. *Brain Research Bulletin* 1992;28:651–653.

8. Greenberg G, Mikulis DJ, Ng K, DeSouza D, Green RE. Use of diffusion tensor imaging to examine subacute white matter injury progression in moderate to severe traumatic brain injury. *Archives of Physical Medicine & Rehabilitation* 2008;89:S45–S50.
9. Ng K, Mikulis DJ, Glazer J, Kabani N, Till C, Greenberg G, Thompson A, Lazinski D, Agid R, Colella B, et al. Magnetic resonance imaging evidence of progression of subacute brain atrophy in moderate to severe traumatic brain injury. *Archives of Physical Medicine & Rehabilitation* 2008;89:S35–S44.
10. Sidaros A, Skimminge A, Liptrot MG, Sidaros K, Engberg AW, Herning M, Paulson OB, Jernigan TL, Rostrup E. Long-term global and regional brain volume changes following severe traumatic brain injury: A longitudinal study with clinical correlates. *Neuroimage* 2009;44:1–8.
11. Sidaros A, Engberg AW, Sidaros K, Liptrot MG, Herning M, Petersen P, Paulson OB, Jernigan TL, Rostrup E. Diffusion tensor imaging during recovery from severe traumatic brain injury and relation to clinical outcome: A longitudinal study. *Brain* 2008;131:559–572.
12. Kolb B, Muhammad A, Gibb R. Searching for factors underlying cerebral plasticity in the normal and injured brain. *Journal of Communication Disorders* 2011;44:503–514.
13. Niogi SN, Mukherjee P, Ghajar J, Johnson C, Kolster RA, Sarkar R, Lee H, Meeker M, Zimmerman RD, Manley GT, et al. Extent of microstructural white matter injury in postconcussive syndrome correlates with impaired cognitive reaction time: A 3T diffusion tensor imaging study of mild traumatic brain injury. *American Journal of Neuroradiology* 2008;29:967–973.
14. Arfanakis K, Houghton VM, Carew JD, Rogers BP, Dempsey RJ, Meyerand ME. Diffusion tensor MR imaging in diffuse axonal injury. *Am J Neuroradiol* 2002;23:794–802.
15. Chan JH, Tsui EY, Peh WC, Fong D, Fok KF, Leung KM, Yuen MK, Fung KK. Diffuse axonal injury: Detection of changes in anisotropy of water diffusion by diffusion-weighted imaging. *Neuroradiology* 2003;45:34–38.
16. Fox RJ, Cronin T, Lin J, Wang X, Sakaie K, Ontaneda D, Mahmoud SY, Lowe MJ, Phillips MD. Measuring myelin repair and axonal loss with diffusion tensor imaging. *American Journal of Neuroradiology* 2011;32:85–91.
17. Huisman TA, Schwamm LH, Schaefer PW, Koroshetz WJ, Shetty-Alva N, Ozsunar Y, Wu O, Sorensen AG. Diffusion tensor imaging as potential biomarker of white matter injury in diffuse axonal injury. *American Journal of Neuroradiology* 2004;25:370–376.
18. Inglese M, Makani S, Johnson G, Cohen BA, Silver JA, Gonen O, Grossman RI. Diffuse axonal injury in mild traumatic brain injury: A diffusion tensor imaging study. *Journal of Neurosurgery* 2005;103:298–303.
19. Nakayama N, Okumura A, Shinoda J, Yasokawa YT, Miwa K, Yoshimura SI, Iwama T. Evidence for white matter disruption in traumatic brain injury without macroscopic lesions. *Journal of Neurology, Neurosurgery & Psychiatry* 2006;77:850–855.
20. Ptak T, Sheridan RL, Rhea JT, Gervasini AA, Yun JH, Curran MA, Borszuk P, Petrovick L, Novelline RA. Cerebral fractional anisotropy score in trauma patients: A new indicator of white matter injury after trauma. *American Journal of Roentgenology* 2003;181:1401–1407.
21. Rugg-Gunn FJ, Symms MR, Barker GJ, Greenwood R, Duncan JS. Diffusion imaging shows abnormalities after blunt head trauma when conventional magnetic resonance imaging is normal. *Journal of Neurology, Neurosurgery & Psychiatry* 2001;70:530–533.
22. Salmond CH, Menon DK, Chatfield DA, Williams GB, Pena A, Sahakian BJ, Pickard JD. Diffusion tensor imaging in chronic head injury survivors: Correlations with learning and memory indices. *Neuroimage* 2006;29:117–124.
23. Tate DF, Bigler ED. Fornix and hippocampal atrophy in traumatic brain injury. *Learning & Memory* 2000;7:442–446.
24. Tsvilivis D, Vann SD, Denby C, Roberts N, Mayes AR, Montaldi D, Aggleton JP. A disproportionate role for the fornix and mammillary bodies in recall versus recognition memory. *Nature Neuroscience* 2008;11:834–842.
25. Chang MC, Kim SH, Kim OL, Bai DS, Jang SH. The relation between fornix injury and memory impairment in patients with diffuse axonal injury: A diffusion tensor imaging study. *Neurorehabilitation* 2010;26:347–353.
26. Hong JH, Jang SH. Degeneration of cingulum and fornix in a patient with traumatic brain injury: Diffuse tensor tractography study. *Journal of Rehabilitation Medicine* 2010;42:979–981.
27. Palacios EM, Fernandez-Espejo D, Junque C, Sanchez-Carrion R, Roig T, Tormos JM, Bargallo N, Vendrell P. Diffusion tensor imaging differences relate to memory deficits in diffuse traumatic brain injury. *BMC Neurology* 2011;23:11–24.
28. Wang JY, Bakhadirov K, Devous Sr MD, Abdi H, McColl R, Moore C, Marquez de la Plata CD, Ding K, Whittemore A, Babcock E, et al. Diffusion tensor tractography of traumatic diffuse axonal injury. *Archives of Neurology* 2008;65:619–626.
29. Xu J, Rasmussen IA, Lagopoulos J, Haberg A. Diffuse axonal injury in severe traumatic brain injury visualized using high-resolution diffusion tensor imaging. *Journal of Neurotrauma* 2007;24:753–765.
30. Zhan W, Boreta L, Gauger G. Magnetic resonance imaging for white matter degradation in fornix following mild traumatic brain injury. San Diego, CA: Medical Imaging 2010: Biomedical Applications in Molecular, Structural, and Functional Imaging Conference; 2010. p 1–7.
31. Farbota KD, Bendlin BB, Alexander AL, Rowley HA, Dempsey RJ, Johnson SC. Longitudinal diffusion tensor imaging and neuropsychological correlates in traumatic brain injury patients. *Frontiers in Human Neuroscience* 2012;6:1006–1018.
32. Rorden C, Karnath HO, Bonilha L. Improving lesion-symptom mapping. *Journal of Cognitive Neuroscience* 2007;19:1081–1088.
33. Smith SM, Jenkinson M, Woolrich MW, Beckmann CF, Behrens TE, Johansen-Berg H, Bannister PR, De Luca M, Drobnjak I, Flitney DE, et al. Advances in functional and structural MR image analysis and implementation as FSL. *Neuroimage* 2004;23:S208–S219.
34. Woolrich MW, Jbabdi S, Patenaude B, Chappell M, Makni S, Behrens T, Beckmann C, Jenkinson M, Smith SM. Bayesian analysis of neuroimaging data in FSL. *Neuroimage* 2009;45:S173–S186.
35. Smith SM. Fast robust automated brain extraction. *Human Brain Mapping* 2002;17:143–155.
36. Smith SM, Jenkinson M, Johansen-Berg H, Rueckert D, Nichols TE, Mackay CE, Watkins KE, Ciccarelli O, Cader MZ, Matthews PM, et al. Tract-based spatial statistics: Voxelwise analysis of multi-subject diffusion data. *Neuroimage* 2006;31:1487–1505.
37. Andersson JLR, Jenkinson M, Smith S. Non-linear optimisation. FMRIB technical report TR07JA1. FMRIB Centre, Oxford, United Kingdom. 2007. Available online at: www.fmrib.ox.ac.uk/analysis/techrep, accessed 2012.
38. Andersson JLR, Jenkinson M, Smith S. Non-linear registration, aka Spatial normalisation FMRIB technical report TR07JA2. FMRIB Centre, Oxford, United Kingdom. 2007. Available online at: www.fmrib.ox.ac.uk/analysis/techrep, accessed 2012.
39. Rueckert D, Sonoda LI, Hayes C, Hill DL, Leach MO, Hawkes DJ. Nonrigid registration using free-form deformations: Application to breast MR images. *IEEE Transactions in Medical Imaging* 1999;18:712–721.
40. Jang SH, Cho SH, Chang MC. Age-related degeneration of the fornix in the human brain: A diffusion tensor imaging study. *International Journal of Neuroscience* 2011;121:94–100.
41. Mori S, Oishi K, Jiang H, Jiang L, Li X, Akhter K, Hua K, Faria AV, Mahmood A, Woods R, et al. Stereotaxic white matter atlas based on diffusion tensor imaging in an ICBM template. *Neuroimage* 2008;40:570–582.
42. Rodriguez-Paez AC, Brunschwig JP, Bramlett HM. Light and electron microscopic assessment of progressive atrophy following moderate traumatic brain injury in the rat. *Acta Neuropathologica* 2005;109:603–616.
43. Johnson VE, Stewart JE, Begbie FD, Trojanowski JQ, Smith DH, Stewart V. Inflammation and white matter degeneration persist for years after a single traumatic brain injury. *Brain* 2013;136:28–42.
44. Smith C, Gentleman SM, Leclercq PD, Murray LS, Griffin WST, Graham DI, Nicoll JAR. The neuroinflammatory response in humans after traumatic brain injury. *Neuropathology and Applied Neurobiology* 2012;n/a–n/a.
45. Bigler ED. Neuroinflammation and the dynamic lesion in traumatic brain injury. *Brain* 2013;136:9–11.
46. Bramlett HM, Dietrich WD, Green EJ, Busto R. Chronic histopathological consequences of fluid-percussion brain injury in

- rats: Effects of post-traumatic hypothermia. *Acta Neuropathologica* 1997;93:190–199.
47. Williams S, Raghupathi R, MacKinnon MA, McIntosh TK, Saatman KE, Graham DI. In situ DNA fragmentation occurs in white matter up to 12 months after head injury in man. *Acta Neuropathologica* 2001;102:581–590.
 48. Bramlett HM, Kraydieh S, Green EJ, Dietrich WD. Temporal and regional patterns of axonal damage following traumatic brain injury: A beta-amyloid precursor protein immunocytochemical study in rats. *Journal of Neuropathology & Experimental Neurology* 1997;56:1132–1141.
 49. Colicos MA, Dixon CE, Dash PK. Delayed, selective neuronal death following experimental cortical impact injury in rats: Possible role in memory deficits. *Brain Research* 1996;739:111–119.
 50. Smith DH, Chen XH, Pierce JE, Wolf JA, Trojanowski JQ, Graham DI, McIntosh TK. Progressive atrophy and neuron death for one year following brain trauma in the rat. *Journal of Neurotrauma* 1997;14:715–727.
 51. Smith DH, Uryu K, Saatman KE, Trojanowski JQ, McIntosh TK. Protein accumulation in traumatic brain injury. *Neuromolecular Medicine* 2003;4:59–72.
 52. Uryu K, Chen XH, Martinez D, Browne KD, Johnson VE, Graham DI, Lee VM, Trojanowski JQ, Smith DH. Multiple proteins implicated in neurodegenerative diseases accumulate in axons after brain trauma in humans. *Experimental Neurology* 2007;208:185–192.
 53. Johnson VE, Stewart W, Smith DH. Widespread tau and amyloid-Beta pathology many years after a single traumatic brain injury in humans. *Brain Pathology* 2012;22:142–149.
 54. Smith DH, Johnson VE, Stewart W. Chronic neuropathologies of single and repetitive TBI: Substrates of dementia? *Nature Reviews Neurology* 2013;9:211–221.
 55. Greer JE, McGinn MJ, Povlishock JT. Diffuse traumatic axonal injury in the mouse induces atrophy, c-Jun activation, and axonal outgrowth in the axotomized neuronal population. *Journal of Neuroscience* 2011;31:5089–5105.
 56. Bigler ED, Maxwell WL. Neuroimaging and neuropathology of TBI. *NeuroRehabilitation* 2011;28:63–74.
 57. Masel BE, DeWitt DS. Traumatic brain injury: A disease process, not an event. *Journal of Neurotrauma* 2010;27:1529–1540.
 58. Hannay HJ, Howieson DB, Loring DW, Fischer JS, Lezak MD. “Neuropathology for neuropsychologists”. In: Lezak MD, Howieson DB, Loring DW, editors. *Neuropsychological assessment*. Oxford, Oxfordshire: Oxford University Press; 2004. p 160.
 59. Bach-y-Rita, P. Theoretical basis for brain plasticity after a TBI. *Brain Injury* 2003;17:643–651.